

# Glaucoma/EMGT Case


Edward Sung, MD  
 Wheaton Eye Clinic  
 Loyola University/Hines VA Hospital  
 University of Illinois at Chicago

## Clinical Course

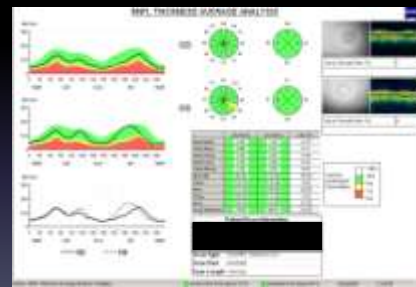
- 67 year-old healthy female of European ancestry
- First seen at the practice in 1983 (age 37)
- First Exam: 20/20 with mild myopia, open angles, IOP 15/14 mmHg, c/d small OU, followed regularly over the next 17 years

Time	IOP/tests	Results
Sept 2000	IOP 25/16 "OHTN" dx	Recheck IOP soon
May 2001	IOP 18/15	Annual checks
August 2004	IOP 27/19	Start drop #1, no effect
Feb 2005	IOP 22 OD	On drop #2 (later, developed follicles)
August 2005	IOP 34/20	First consult; Had stopped gtts, order vf oct
May 2006	IOP 22/16 on Xal... +PXE	1 <sup>st</sup> time with PXF; gtts, laser x 3 years OD
Nov 2010	IOP 31/18	Surgery performed
Jan 2014	IOP 10/12	IOP ok OD without gtts, one drop OS

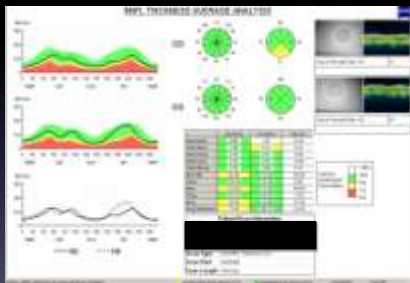
## HVF 2005




## OCT 2005



## OCT 2009



## HVF 2011



## EMGT-related questions

- Issues to consider
  - When does OHTN cross over into glaucoma?
    - VF change? Disc change? OCT change?
  - When should treatment be started?
  - What role does PXF/exfoliation play in glaucoma severity?